

An aerial photograph of a tropical bay with turquoise water and a forested island. The water is a vibrant blue-green, and the island is covered in dense green vegetation. The bay is surrounded by a sandy beach and some buildings are visible in the foreground.

# Cas clinique SIFEM Junior

*Quand l'ovaire nage entre deux eaux*

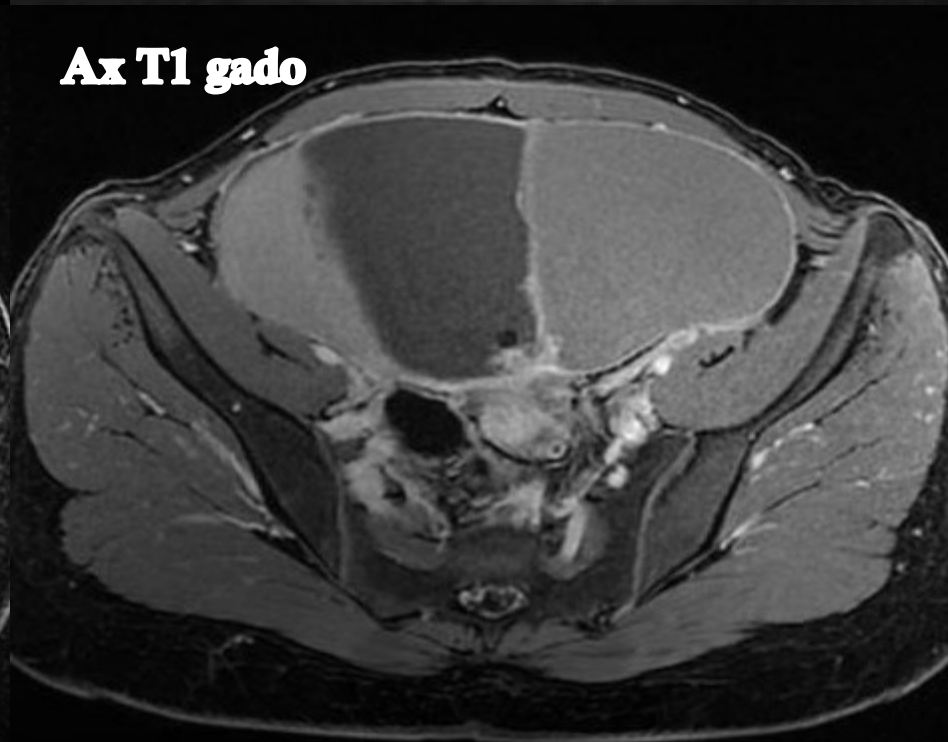
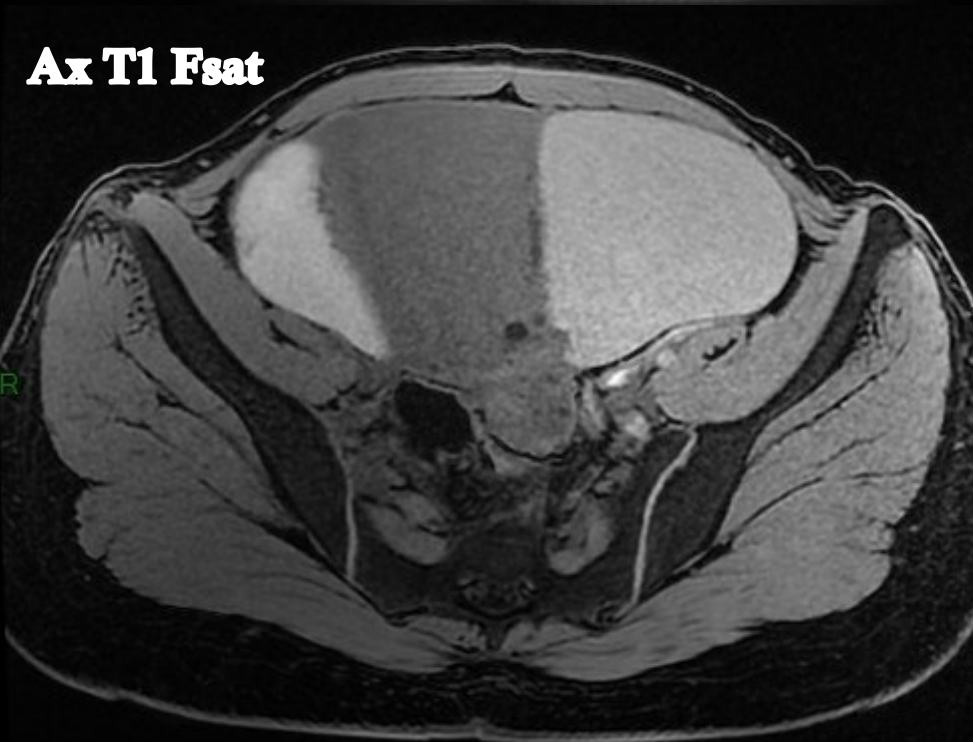
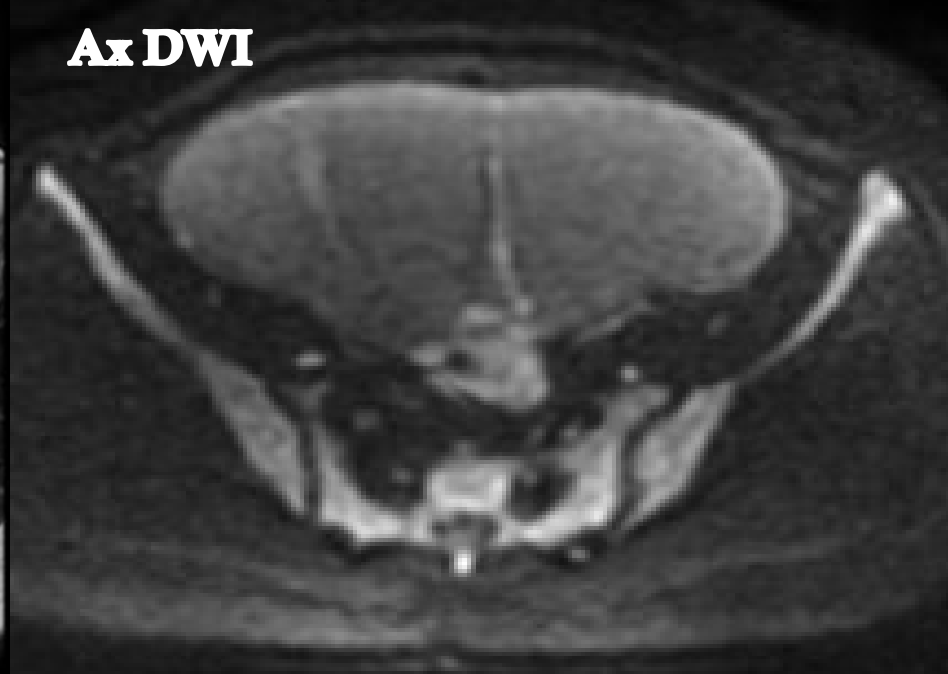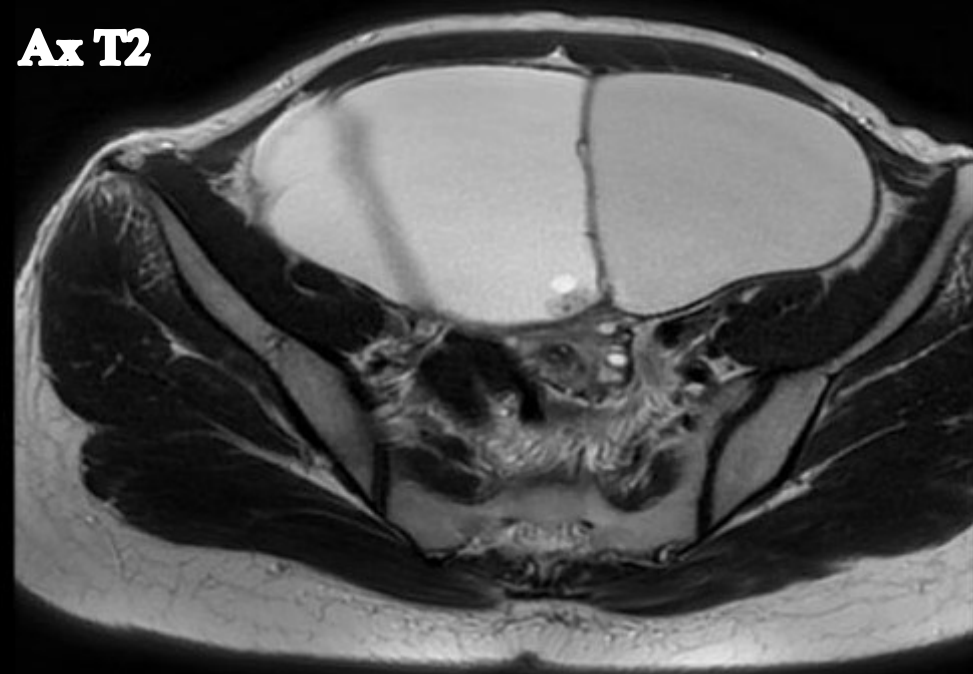
Déborah MOUSTIN

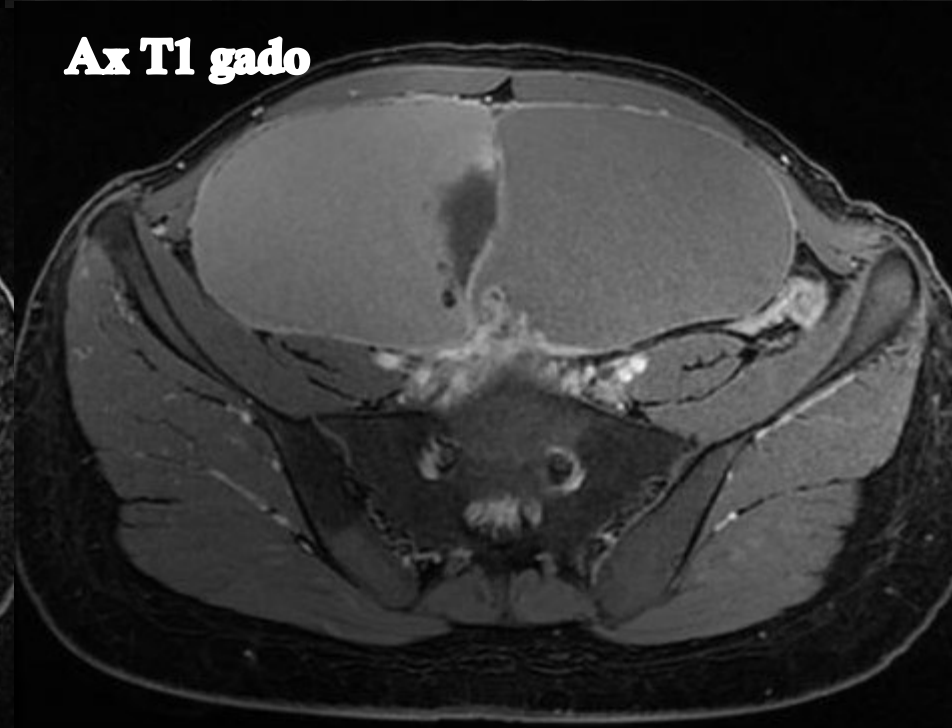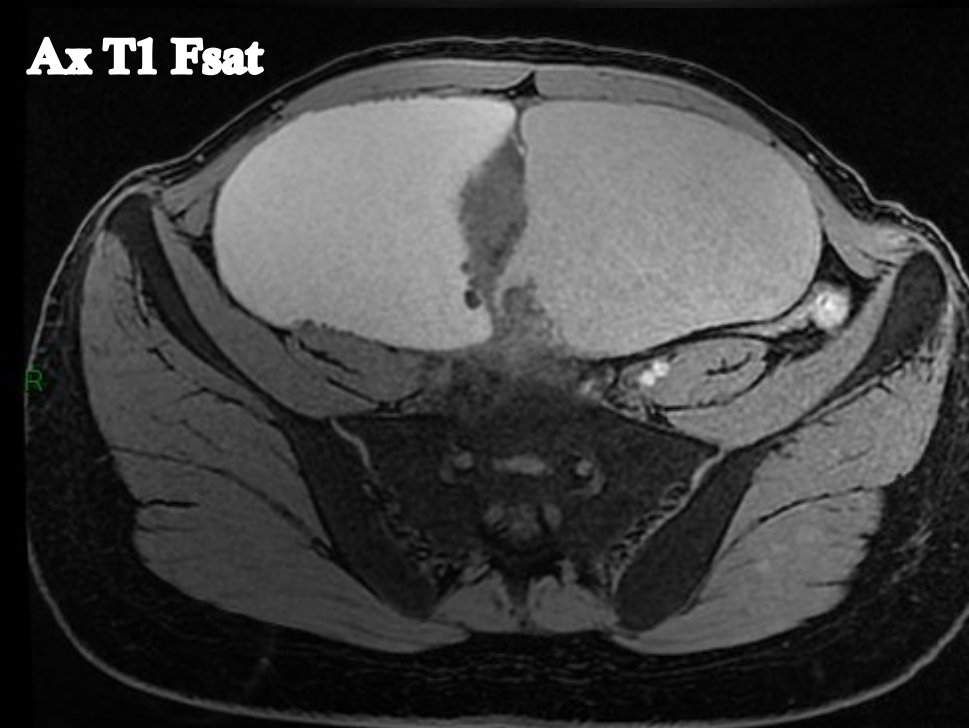

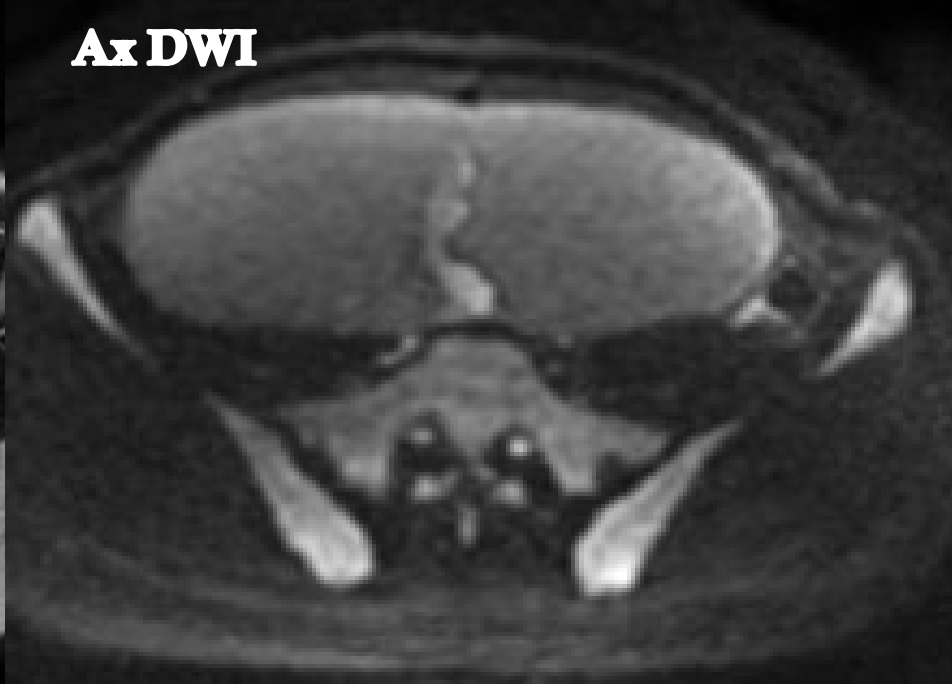
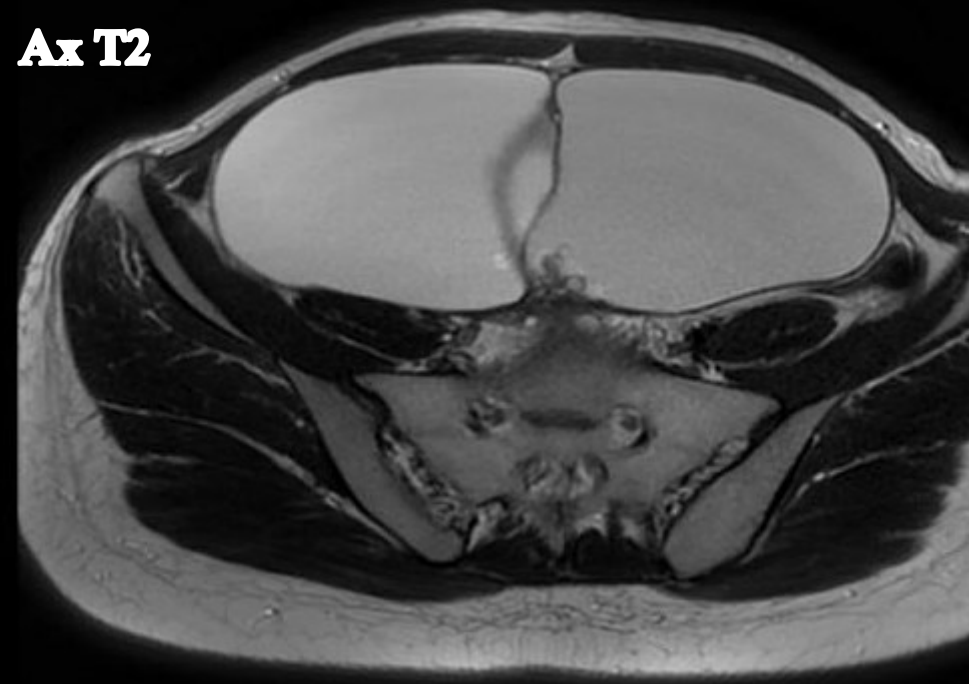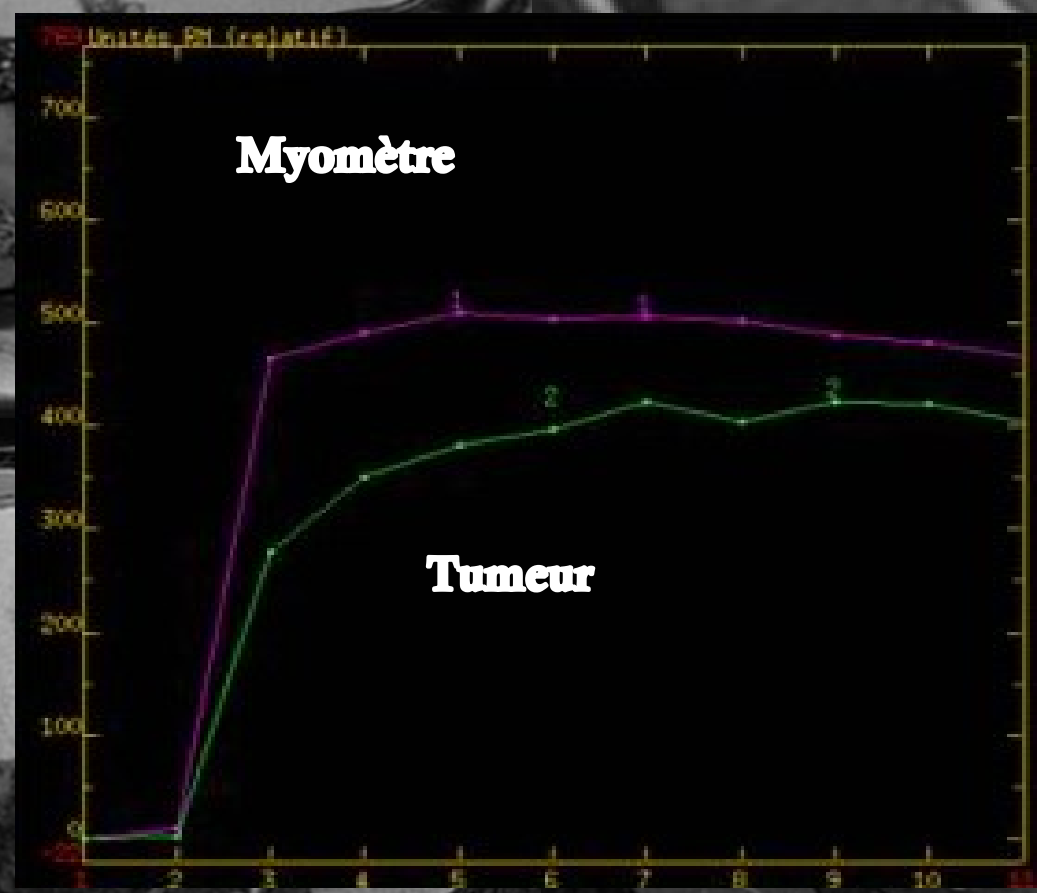
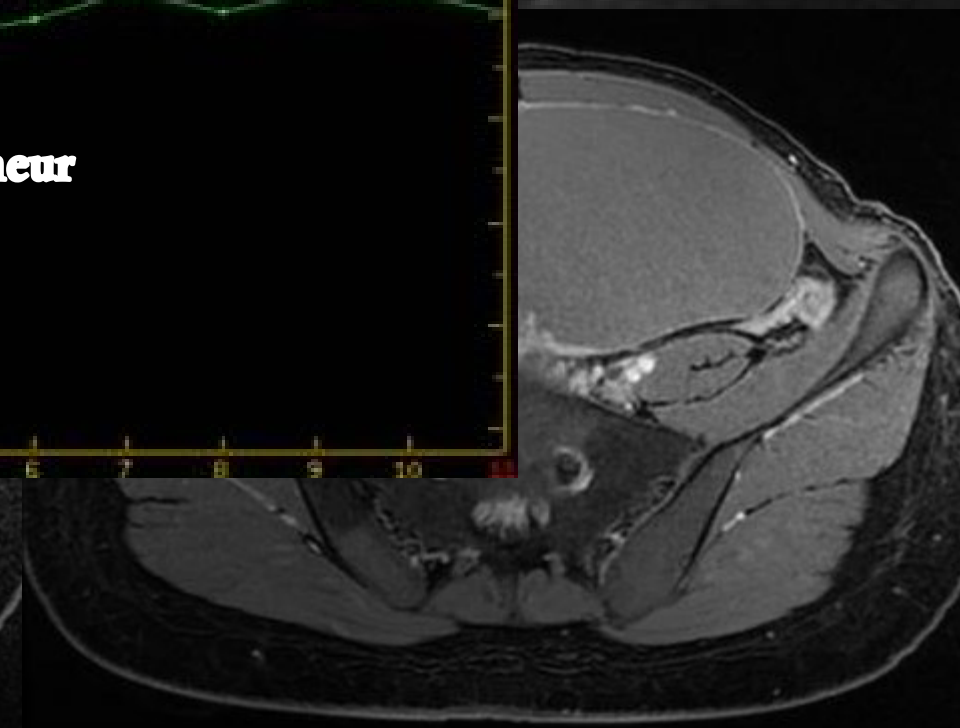
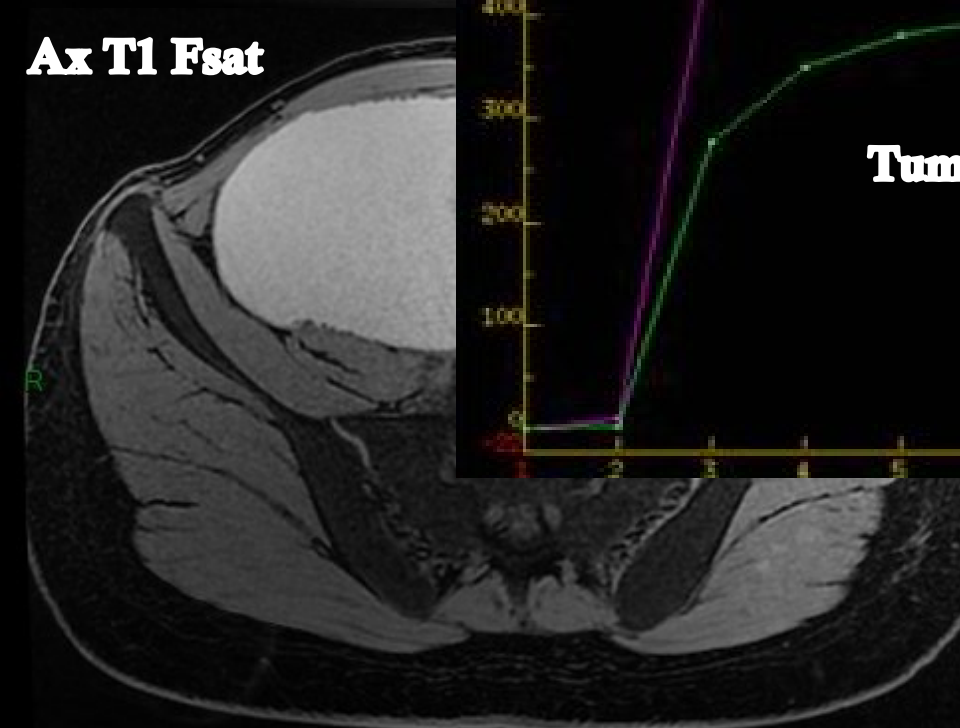
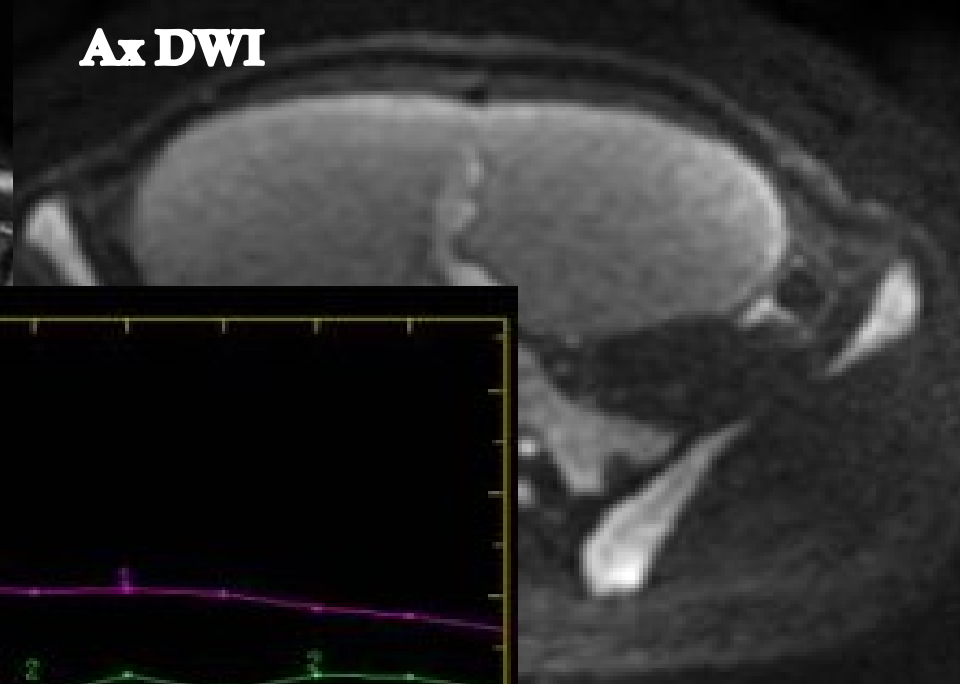
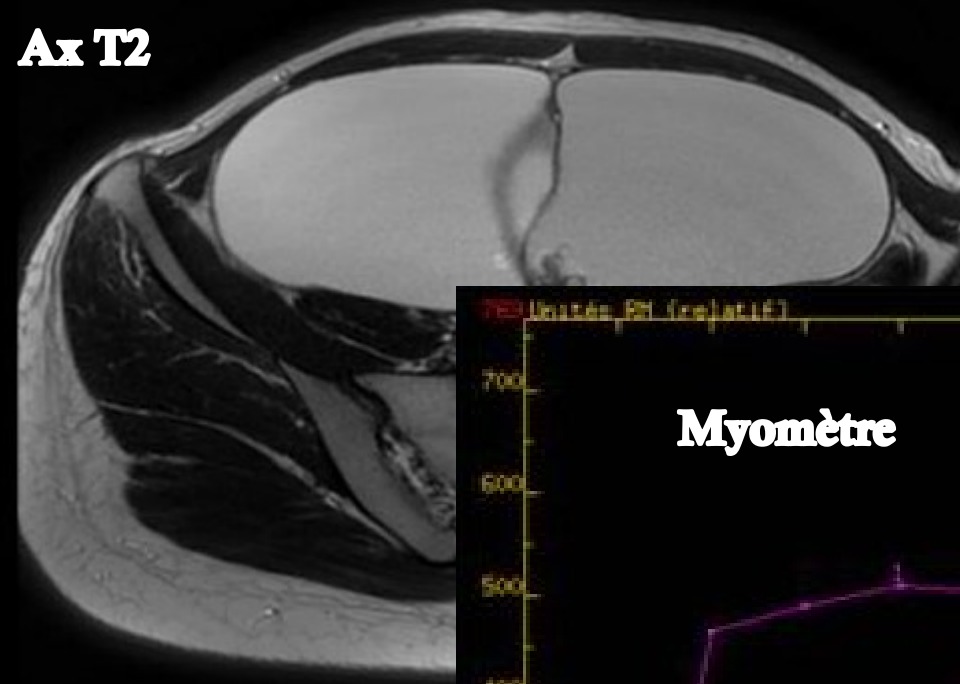
# Cas clinique

- ◆ Patiente de 28 ans
- ◆ Nulligeste
- ◆ Pas d'antécédent personnel de cancer du sein ou de l'ovaire
- ◆ Adressée pour caractérisation d'une masse pelvienne en IRM









# Analyse descriptive

**TUMEUR SERO-MUCINEUSE  
FRONTIERE**